

# Tuboovarian Abscess Accompanying Pregnancy

## Gebelikte Tuboovaryan Apse

 Recai PABUÇCU<sup>a</sup>,  Aslı YARCI GÜRSOY<sup>a</sup>,  Mine KİSELİ<sup>a</sup>,  
 Emre Göksan PABUÇCU<sup>a</sup>,  Müge KESKİN<sup>a</sup>

<sup>a</sup>Department of Obstetrics and Gynecology, Ufuk University Faculty of Medicine, Ankara, Turkey

### ABSTRACT

Tuboovarian abscess (TOA) in pregnancy is a quite rare situation, preceded by oocyte retrieval during assisted reproductive treatment (ART) in most of the cases. There is not a consensus in the literature about the management and only few cases have been reported. Conservative management like drainage or surgical intervention are alternative strategies for the treatment. Herein we reported a pregnant case with TOA managed by a conservative approach.

**Keywords:** Tuboovarian abscess; pregnancy; management

### ÖZET

Gebelikte tuboovaryan apse (TOA) oldukça nadir görülen ve çoğu vakada yardımcı üreme tedavileri sürecinde yapılan oosit toplanması sonrasında gelişen bir patolojidir. Literatürde az sayıda vakaya ait veri mevcuttur ve bu tür vakaların yönetimine dair bir fikir birliği bulunmamaktadır. Tedavide, drenaj gibi konservatif yaklaşımlar ya da cerrahi girişim tercih edilebilir. Burada, gebelikte TOA tanısı alan bir hastanın konservatif yaklaşımla yönetiminden bahsedilecektir.

**Anahtar Kelimeler:** Tuboovaryan apse; gebelik; tedavi

TJRMS 2018;2(3):124-6

Pelvic infection is the second most common complication of transvaginal oocyte retrieval after bleeding. The infection is rarely complicated with tuboovarian abscess (TOA) in 0.03 % of the cases.<sup>1,2</sup> Although most of the pelvic infections are presented within days after oocyte retrieval, it takes more time for TOA to be clinically apparent and the patients are presented mostly within 3 weeks after the procedure.<sup>3</sup>

TOA during pregnancy is extremely rare in the literature and there are only few cases resulting with delivery of healthy infants (7 cases among 12 TOA cases in pregnancy).<sup>4</sup> Different management strategies

Geliş Tarihi/Received: 22.12.2018

Kabul Tarihi/Accepted: 26.12.2018

Yazışma Adresi/Correspondence:

Aslı YARCI GÜRSOY

Ufuk University Faculty of Medicine, Department of Obstetrics and Gynecology, Ankara, TURKEY/TÜRKİYE  
asliyarci@gmail.com

The case was presented in XXVI. European Congress of Perinatal Medicine as poster presentation in St. Petersburg, Russia.

Copyright © 2018 by Üreme Tıbbi Cerrahi Eğitim Araştırma ve Uygulama Vakfı

have been reported including medical management, drainage and surgical intervention. Herein we reported a pregnant case with TOA overlapping severe endometriosis and managed conservatively resulting with delivery of a healthy infant.

## CASE REPORT

35 year-old G1, 15-week pregnant woman who was infertile and got pregnant by assisted reproduction techniques (ART) at her third cycle, was admitted to emergency department with fever and pelvic pain. She had history of laparoscopy for severe (Stage 4) endometriosis accompanied by bilateral endometriomas which were infected after oocyte retrieval and treated by drainage and antibiotherapy. Physical examination revealed bilateral lower quadrant tenderness and subfebrile fever. The laboratory results pointed out quite high WBC ( $19.5 \times 10^3/\mu\text{L}$ ) and C-reactive protein (138 mg/L) indicating a serious infectious morbidity. Ultrasonographic examination confirmed a healthy fetus in the 15<sup>th</sup> gestational week, and a 113x68 mm multiloculated mass with a heterogeneous content consistent with a pelvic abscess possibly overlapping an endometrioma (Figure 1).

Neither the clinical nor the laboratory parameters were enhanced and the ultrasonographic findings persisted despite parenteral antibiotherapy [ceftriaxon (1 gr bid) and metronidazole (500 mg bid)]. Because, the mass was thought to be a pelvic abscess, and no improvement was observed with antibiotherapy, drainage was planned. The mass was drained transvaginally via sonographic guidance and culture of the purulent material was negative for any microorganisms. The clinical and laboratory findings were improved after the drainage of the pelvic abscess and parenteral antibiotherapy and the patient was discharged uneventfully 1 week after the drainage procedure. In the follow up, the patient delivered a 3060 gr healthy fetus with 9/10 APGAR score by cesarean section due to placenta previa accompanied by vaginal bleeding when she was 36 week-4 day pregnant. During the cesarean section, both adnexia were densely adherent to the uterus posteri-

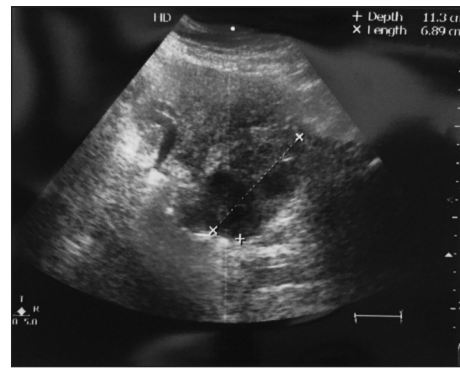


FIGURE 1: Ultrasonographic appearance of the adnexial mass.

orly but no residual lesion similar with the abscess was observed and no complications were reported in the postoperative period.

## CONCLUSION

TOA is a quite rare situation in pregnancy, with a few cases reported ending up with delivery of a healthy newborn.<sup>4</sup> The cases are mostly presented with pelvic pain accompanied by subfebrile/prominent fever. Imaging technologies like ultrasonography and magnetic resonance imaging are valuable in the diagnosis especially during pregnancy. Oocyte retrieval history in the presence of endometrioma(s) is highly suggestive of etiology in the present case.<sup>4</sup> Pelvic infections after oocyte retrieval are possibly due to either direct inoculation of the microorganisms from the vagina/colon or reactivation of a latent pelvic disease.<sup>3</sup> Endometriosis predisposes the infection and accompanies about 70% of the cases reported in the literature.<sup>4</sup> In the current case, the patient was not operated before ART since the endometriomas were bilateral and preservation of the ovarian reserve was preferred but then secondary infection possibly due to oocyte retrieval made surgical intervention compulsory before further ART treatment in the prepregnancy period.

The culture of the abscess material is mostly negative for microorganisms, as in this case and microorganisms might be isolated in only 23% of the cases.<sup>5</sup> If it is positive, anaerobic opportunists such as *Escherichia coli*, *Bacteroides fragilis*, *Enterococcus*, and *Peptococcus* are the most common mi-

croorganisms.<sup>2</sup> Ampiric parenteral antibiotherapy usually gets the lesion under control in most of the cases.

Laparotomy, laparoscopy and ultrasonography guided drainage are alternative management strategies in such cases. The treatment modality is usually selected according to the clinical situation of the pregnant woman, severity of the lesion and viability of the fetus. Most of the reported cases in literature were managed with, surgical intervention either with laparoscopy or laparotomy. In case of prominent signs of peritonitis, emergency laparotomy might be indicated and la-

paroscopy might be an alternative if the gestational week is appropriate and elective surgical intervention is planned however early pregnancy losses were also reported following laparoscopic management.<sup>4,6,7</sup> Percutaneous drainage or drainage by colpotomy in guidance of ultrasonography are, alternative conservative management strategies reported in case reports.<sup>4</sup> In the current case, oocyte pick up needle in the guidance of ultrasonography was used to drain the purulent material. The drainage was successful enough to let the pregnancy proceed and end up with delivery of a healthy infant.

## REFERENCES

1. Aragona C, Mohamed MA, Espinola MS, Linari A, Pecorini F, Micara G, et al. Clinical complications after transvaginal oocyte retrieval in 7,098 IVF cycles. *Fertil Steril.* 2011;1:293-4.
2. Asemota OA, Girda E, Dueñas O, Neal-Perry G, Pollack SE. Actinomycosis pelvic abscess after in vitro fertilization. *Fertil Steril.* 2013;100(2):408-11.
3. Younis JS, Ezra Y, Laufer N, Ohel G. Late manifestation of pelvic abscess following oocyte retrieval, for in vitro fertilization, in patients with severe endometriosis and ovarian endometriomata. *J Assist Reprod Genet.* 1997;6:343-6.
4. Kim JW, Lee WS, Yoon TK, Han JE. Term delivery following tuboovarian abscess after in vitro fertilization and embryo transfer. *Am J Obstet Gynecol.* 2013;208(5):e3-6.
5. Corsi PJ, Johnson SC, Gonik B, Hendrix SL, McNeeley SG Jr, Diamond MP. Transvaginal ultrasound-guided aspiration of pelvic abscesses. *Infect Dis Obstet Gynecol.* 1999;7(5):216-21.
6. Laohaburanakit P, Treevijitsilp P, Tantawichian T, Bunyavejchevin S. Ruptured tuboovarian abscess in late pregnancy. A case report. *J Reprod Med.* 1999;44(6):551-5.
7. Pabuccu EG, Taskin S, Atabekoglu C, Sonmez M. Early pregnancy loss following laparoscopic management of ovarian abscess secondary to oocyteretrieval. *Int J Fertil Steril.* 2014;8(3):341-6.