

Cervical Ectopic Pregnancy of 45,XO Embryo After In Vitro Fertilization/Embryo Transfer İn Vitro Fertilizasyon/Embriyo Transferi Sonrası 45,XO Embriyonun Servikal Ektopik Gebeliği

Gülnaz ŞAHİN,^a Mesut BALA,^b Aysin AKDOĞAN,^a Ege TAVMERGEN GÖKER,^{a,c} Erol TAVMERGEN^{a,c}

^aDepartment of Obstetrics and Gynecology, Ege University Family Planning and Infertility Research and Application Center, İzmir

^bClinic of Obstetrics and Gynecology, Diyarbakır Obstetrics and Gynecology Hospital, Diyarbakır

^cDepartment of Obstetrics and Gynecology, Ege University Faculty of Medicine, İzmir

ABSTRACT

We report a case of anembryonic pregnancy located in the cervico-isthmic region of the uterus following in vitro fertilization (IVF)/embryo transfer (ET) treatment cycle. Cervical pregnancy was diagnosed during 7 weeks of gestation and treated with successful aspiration and curettage. Cytogenetic analysis of abortus material was consistent with 45,XO, Turner syndrome. Early diagnosis of cervico-isthmic pregnancy is important and critical for effective conservative management.

Key Words: Ectopic pregnancy; 45 XO; Turner syndrome; in vitro fertilization

ÖZET

İn vitro fertilizasyon/embriyo transferi tedavi siklusunu sonrası uterusun serviko-istmik alanında lokalize bir anembriyonik gebelik olgusu rapor edildi. Tanı, 7. gebelik haftasında konarak aspirasyon ve küretaj işlemi ile tedavi edildi. Küretaj materyalinin sitogenetik test sonucu 45,XO Turner sendromu ile uyumu izlendi. Serviko-istmik gebeliğin erken tanısı etkin konservatif yaklaşım için önemli ve kritiktir.

Anahtar Kelimeler: Ektopik gebelik; 45 XO; Turner sendromu; in vitro fertilizasyon

TJRMS 2017;1(2):116-9

Cervical pregnancy is usually considered as a life threatening event. It is a rare form of ectopic gestation and accounts for less than 1% of all pregnancies.¹ Cervical pregnancy was defined as implantation of the gestation in the endocervical canal. The incidence is approximately 1 in 2500-12000 pregnancies.² It is a well known complication of ART procedures. Early diagnosis is important and allows conservative treatment option to preserve fertility. Hysterectomy was the only treatment for cervical pregnancy in the past.² Current treatment modalities include aspiration curettage with hypogastric/uterine artery embolization, curettage and local prostoglandin injection, insertion of foley catheter in the cervical canal after curettage, local administration of methotrexate (MTX) with/without local potassium chloride, systemic administration of MTX and hysteroscopic resection of the gestation in conjunction with uterine artery embolization.³⁻⁵ Early diagnosis is important to prevent serious complications such as

Geliş Tarihi/Received: 10.01.2017

Kabul Tarihi/Accepted: 27.04.2017

Yazışma Adresi/Correspondence:

Gülnaz ŞAHİN

Ege University Family Planning and Infertility Research and Application Center, Department of Obstetrics and Gynecology, İzmir, TURKEY/TÜRKİYE
gsahini@msn.com

Copyright © 2017 by Üreme Tıbbi Cerrahi Eğitim Araştırma ve Uygulama Vakfı

massive hemorrhage. We present a case with cervical ectopic pregnancy following IVF/ICSI and ET in the current report.

CASE REPORT

A 28 year old woman was referred to our center for secondary infertility. She was married for 8 years. The etiology of infertility was male factor with severe oligospermia. Her first spontaneous pregnancy was terminated with dilatation and curettage for missed abortion at 6 weeks of gestation a year ago. The patient underwent IVF/ICSI cycle. 10 oocytes were retrieved and 9 of them were mature. ICSI was performed to all oocytes. Embryo was transferred under abdominal ultrasound guidance. Initial serum hCG, progesteron and E2 levels, 14 days after embryo transfer were 49 mIU/ml, 60 ng/ml and 926pg/ml, respectively. Daily progesterone vaginal gel and weekly hCG 5000 IU ampoule intramuscularly were prescribed. Six days after the initial hCG test, the level raised to the 349 IU/ml. Serum hCG, progesterone and estradiol levels were measured every 3-7 days (Figure 1). The serum hCG levels increased moderately.

Transvaginal ultrasound (TVUSG) examination 4 weeks after ET, demonstrated an empty uterine cavity with a 9 mm gestational sac located in the cervicoisthmic area and serum hCG level was 1861 IU/ml. Follow up ultrasound examination after one week was consistent with slightly growing anembryonic gestational sac in the same localization. 10x18 mm gestational sac in the cervikoisthmic localization was observed by

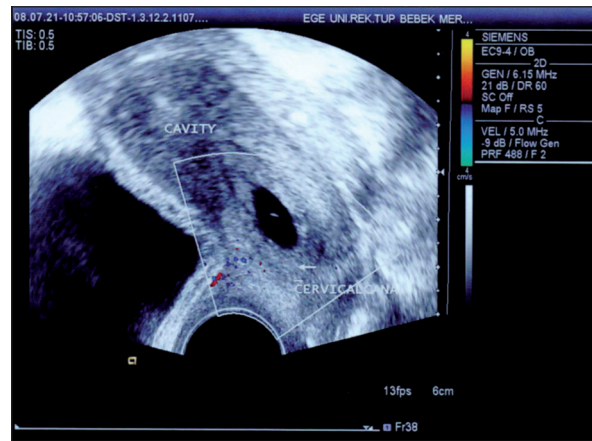


FIGURE 2a: Gestational sac located in the cervico-isthmic area.

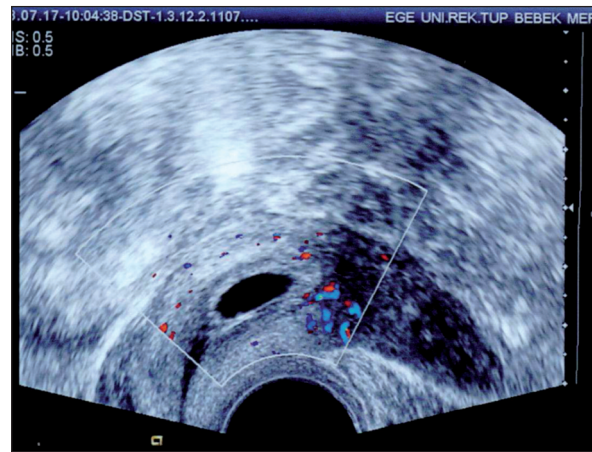


FIGURE 2b: Doppler image of trophoblastic vessels.

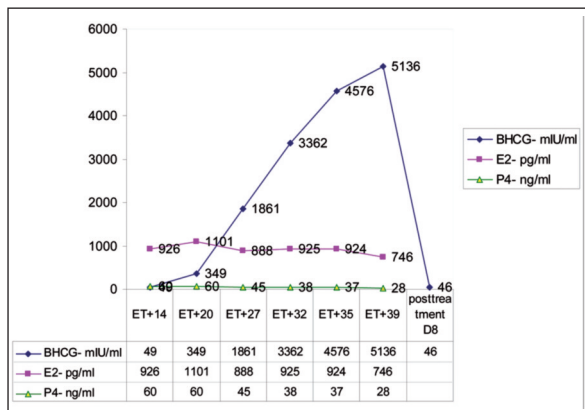


FIGURE 1: Follow-up for hormone levels after embryo transfer.

TVUSG examination in 7weeks and 4 days of gestation. The yolk sac and embryonic pole were not visible. Doppler sonography also revealed trophoblastic vessels in the same area (Figure 2a and 2b). Confirmation of cervical ectopic pregnancy was informed and treatment options were discussed with the patient and her family. Dilatation and aspiration curettage was successfully performed under ultrasound guidance.

The procedure was uneventful, per and post-operative abnormal bleeding was not observed. The abortion material was sent for cytogenetic analysis. The patient was discharged from the hospital the following day, without complication. Follow up ultrasound examination one week after the procedure demonstrated a normal cavity and cervical

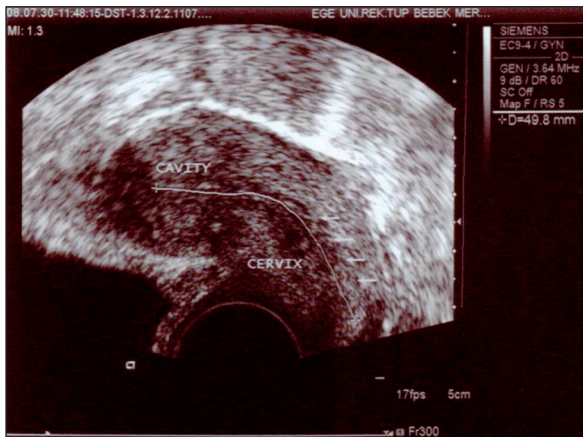


FIGURE 2c: Linear image of the uterine cavity and cervical canal one week after dilatation and curettage.

canal (Figure 2c). The cytogenetic analysis was consistent with 45 XO Turner Syndrome. Patient's peripheral blood karyotype analysis from peripheral blood also demonstrated mosaicism involving normal and 45,XO cells (45 X[4%]/46 XX[96%]). The informed consent was obtained from the patient for the current case report.

DISCUSSION

Several risk factors for ectopic pregnancies are prior dilatation and curettage, cesarean section and pelvic inflammatory disease. There is an overall increase in the incidence of cervical and other sites of ectopic pregnancies with the advent of specific ART technologies.⁶ One of the explanations for this condition focus on the the embryo transfer techniques. Insertion of the transfer catheter into the uterine cavity under ultrasound guidance is suggested to make sure the tip of the catheter is in the right place. Alterations in hormonal milieu and endometrial receptivity secondary to controlled ovarian stimulation are proposed as risk factors for ectopic pregnancies after IVF. A history of tubal

factor infertility and pelvic inflammatory disease are significant risk factors for ectopic pregnancies after IVF.⁷

Although the most common site for ectopic pregnancies are uterine tubes, unusual locations such as cornual, isthmic or cervical sites can be observed. Serial serum hCG and TVUSG monitoring after IVF, leads to early diagnosis of the abnormal location and development of the pregnancy. This approach also provides a chance for conservative managements especially when the diagnosis is made in early first trimester. Dilatation and curettage either with or without cervical balloon tamponade, hysteroscopic resection, embolization of uterine arteries, systemic or local metotrexate therapies are fertility conserving procedures. Serial monitoring of serum hCG and TVUSG allowed early diagnosis of anembryonic cervicoisthmic pregnancy and treatment by successful dilatation and curettage without bleeding, in the current case. Moreover the genetic analysis of the abortus material revealed 45, XO Turner syndrome. The proportions of chromosomal abnormalities in ectopic pregnancies are as high as those in early spontaneous abortions.⁸ Embryos with genetic abnormalities may result wiht abnormal implantation of gestations. Following the diagnosis of 45,XO of the gestational material, the patient's karyotype analysis from peripheral blood also revealed mosaicism involving normal and 45,XO cells (45 X[4%]/46 XX[96%]) in the current case.

In conclusion, early diagnosis of cervicoisthmic pregnancies enables conservative management of patients especially following the ART procedures. Embryonic genome may also contribute to the etiology of ectopic pregnancies. We suggest genetic testing of the ectopic pregnancy material if possible, especially after ART treatments.

REFERENCES

1. Singh S. Diagnosis and management of cervical ectopic pregnancy. *J Hum Reprod Sci* 2013;6(4):273-6.
2. Cepni I, Ocal P, Erkan S, Erzik B. Conservative treatment of cervical ectopic pregnancy with transvaginal ultrasound-guided aspiration and single-dose methotrexate. *Fertil Steril* 2004;81(4):1130-2.
3. Hu J, Tao X, Yin L, Shi Y. Successful conservative treatment of cervical pregnancy with uterine artery embolization followed by curettage: a report of 19 cases. *BJOG* 2016;123 Suppl 3:97-102.
4. Fylstra DL. Cervical pregnancy: 13 cases treated with suction curettage and balloon tamponade. *Am J Obstet Gynecol* 2014; 210(6):581.e1-5
5. Jeng CJ, Ko ML, Shen J. Transvaginal ultrasound-guided treatment of cervical pregnancy. *Obstet Gynecol* 2007;109(5):1076-82.
6. Clayton HB, Schieve LA, Peterson HB, Jamieson DJ, Reynolds MA, Wright VC. Ectopic pregnancy risk with assisted reproductive technology procedures. *Obstet Gynaecol* 2006;107:595-604.
7. Refaat B, Dalton E, Ledger WL. Ectopic pregnancy secondary to in vitro fertilisation-embryo transfer: pathogenic mechanisms and management strategies. *Reprod Biol Endocrinol* 2015;13:30.
8. Job-Spira N, Coste J, Bouyer J, Tharaux-Deneux C, Fernandez H. Chromosomal abnormalities and ectopic pregnancy? New directions for aetiological research. *Hum Reprod* 1996;11(2):239-42.